

Variation of b Value for Axial DWI Prostate MR Imaging in Cancer: Which b Value is Optimal?

Nurul Dwi Agustina¹, Fani Susanto², Hernastiti Sedya Utami³, Lujeng Agus Setiarso⁴,
Muhammad Faisal⁵

^{1,2,3}Faculty of Health Sciences, Universitas Muhammadiyah Purwokerto, Indonesia

⁴Radiology Instalation, RSUD dr. R. Goeteng Taroenadibrata Purbalingga, Indonesia

⁵Department of Biomedical Sciences and Biomedical Engineering, Faculty of Medicine,
Prince of Songkla University, Thailand

ARTICLE INFO

Article history:

DOI:

[10.30595/pshms.v5i.965](https://doi.org/10.30595/pshms.v5i.965)

Submitted:

Oct 13, 2023

Accepted:

Feb 25, 2024

Published:

Mar 20, 2024

Keywords:

DWI, MRI Prostat, Cancer, b value

ABSTRACT

Background: Diffusion Weighted Imaging (DWI) is a technique that visualizes the movement of water molecules from areas of higher to lower concentration. In DWI sequences, the b-value parameter affects the signal intensity in the images. The objective of this study is to describe the differences in anatomical image information between b-value variations of 1500s/mm², 2000s/mm², and 2500s/mm² in MRI prostate case cancer and to determine the most optimal b-value. Method: This study used a pre-exeachmental approach with a 1.5T Philips MRI machine at a private hospital in South Jakarta from March to April 2023. The sample consisted of 12 Prostate MRI images with DWI sequences and different b-values. Visual grading assessment was eachformed by three radiology specialists, and the data were analyzed using the Friedman test in SPSS. Results: The results showed a significant difference in anatomical image information based on the b-value variations used, with a p-value of 0.05 (0.02). The highest mean rank was obtained from the Friedman test for the b-value of 2000s/mm². Conclusion: The significant difference in anatomical image information occurred due to differences in signal intensity and noise levels. Prostate cancer tissues appeared more hyperintense with lower noise in images with higher b-values, and vice versa. Additionally, the b-value of 2000s/mm² resulted in the most optimal signal intensity and noise level. In conclusion, the use of b-value variations in axial DWI images of prostate cancer Prostate MRI to differences in anatomical image information, with the most optimal image information observed at a b-value of 2000s/mm².

This work is licensed under a [Creative Commons Attribution 4.0 International License](https://creativecommons.org/licenses/by/4.0/).



Corresponding Author:

Fani Susanto

Faculty of Health Sciences, Universitas Muhammadiyah Purwokerto,
Soepardjo Rustam Street KM. 7, Banyumas, Indonesia

Email: fanisusanto@ump.ac.id

1. INTRODUCTION

Prostate cancer is the fourth or second most common cancer in men. Based on data from the American Cancer Society, it is predicted that in 2021 there will be 248,000 new cases of prostate cancer in the United States with 34,000 deaths. According to data from the Global Burden of Cancer (GLOBACAN) in 2020,

Proceedings homepage: <https://conferenceproceedings.ump.ac.id/index.php/pshms/issue/view/30>

prostate cancer is the 5th most common type of cancer suffered by men in Indonesia, however, cancer sufferers usually present in an advanced stage with a Gleason score of 6-10. One of the modalities for diagnosing prostate cancer is Magnetic Resonance Imaging (MRI) [1].

Prostate MRI is an MRI examination of the male pelvis which is used to diagnose prostate gland pathology such as prostatitis, benign prostate hyperplasia and prostate cancer [2]. Prostate MRI examination requires several sequences, one of which is DWI. DWI is sensitive to the movement of water molecules by using diffusion coding gradients [3]. DWI has been found to be effective in evaluating the pathological grade of cancer which is divided into 5 groups according to Gleason score, tumor cell density, proliferation index, and glioma prognosis. In clinical practice, DWI is influenced by the b value parameter which is usually obtained with a value of 1,000 s/mm² or b value [4].

Who conducted a study on 29 patients, diffusion images were assessed as better using a high resolution b value of 1,500 s/mm²[5]. Conducted a DWI sequence study of prostate cancer cases in 80 patients, using two observer radiologists and found that DWI with b-2000 s/mm² was considered superior to b-1000 s/mm² for prostate cancer detection [6]. Calculated very high computed b values of > 2000 s/mm² and ADC maps for each of 14 patients, concluded that DWI is able to provide better contrast between prostate tumors and underlying tissue [7].

Based on the results of observations made at the Radiology Installation of the South Jakarta Private Hospital, the Prostate MRI examination protocol in cancer cases is carried out with the same routine protocol for every other prostate MRI examination, namely using a survey sequence, T2 TSE Axial, T1 TSE Axial, T2 STIR. Coronal, T2 TSE Sagittal, T2 TSE Axial Oblique, T2 TSE Coronal Oblique, and DWI sequence. Especially for the DWI sequence in this case, it uses low b values of 0 s/mm², 500 s/mm², 1000 s/mm² and 1400 s/mm², so using all of these b values requires a long scan time. And until now it has not been determined what the optimal b value is to visualize indications of cancer on prostate MRI. The purpose of this study is to describe the difference in anatomical image information from variations in b values of 1500 s / mm², 2000 s / mm² and 2500 s / mm² in MRI of prostate cancer cases and to describe the most optimal b value.

2. RESEARCH METHOD

This study uses a type of quantitative research with a pre-experimental approach. This study conducted a study of Prostate MRI examination in Cancer Cases with DWI Axial Section Sequences using b values between 1500 s/mm², 2000 s/mm² and 2500 s/mm² with the aim of knowing the differences between the three variations of the b values and obtaining Prostate MRI images with b the most optimal value. This study used MR Philips 1.5 Tesla in March-April at the South Jakarta Private Hospital.

The sample in this study used 12 radiographic images with a variation of b value which was carried out by analyzing the differences in image information by 3 observers, namely 3 radiology specialists who had worked for at least 5 years in diagnostic radiology services.

The assessment was carried out by visual grading by the observer by filling out a questionnaire in the form of a checklist on the anatomical criteria table for the b value variations of 1500 s/mm², 2000 s/mm² and 2500 s/mm² to find out the differences and the most optimal use of the b value variation for cancer cases. with a questionnaire format using a Likert scale totaling 3, namely a value of 1 means the anatomy is "Unclear", a value of 2 means "Less clear", a value of 3 means "Clear". Data analysis used bivariate analysis by conducting the Friedman test.

3. RESULT AND DISCUSSIONS

This research was conducted using 4 male patients who had a clinical history of cancer, an average age of over 70 years and were willing to undergo an MRI prostate examination. In medical research, the number of patient samples in the study is very important to ensure the accuracy of the research results. The more patient samples in the research, the greater the possibility that the research results can be applied to a wider population [8].

Interobserver Agreement Analysis

The results of the observer assessment were carried out by intra-observer agreement analysis (Cohen's Kappa) on samples to determine the level of agreement between observers on image assessment with variations of b values 1500 s/mm², 2000 s/mm² and 2500 s/mm². The following are the results of the Cohen's Kappa statistical test:

Table 1. The results of the Cohen's Kappa observer test on the assessment of DWI Axial image information on prostate MRI in cancer cases between b values 1500 s/mm², 2000 s/mm² and 2500 s/mm²

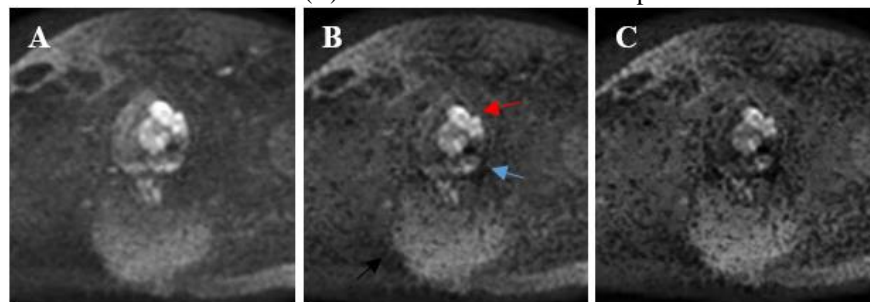
No	b value	Agreement Level			Average	Amount of data
		O1*O2	O1*O3	O2*O3		
1	1500 s/mm ²	0,541	0,323	0,441	0,435	84
2	2000 s/mm ²	0,642	0,706	0,820	0,722	84
3	2500 s/mm ²	0,664	0,668	0,559	0,630	84

Information : O1 : Observer 1, O2 : Observer 2 dan O3 : Observer 3

Based on the statistical test results in Table 1. above, it was found that the level of agreement in the assessment of the three variations with b values of 1500 s/mm², 2000 s/mm² and 2500 s/mm² each had an average p-value above 0.40. This means that the assessment between observers shows a fairly good (fair) level of agreement.

The following is Analysis of differences in DWI Axial anatomical image information on prostate MRI in cancer cases between b values 1500 s/mm², 2000 s/mm² and 2500 s/mm² from a sample image of the b value results on the DWI Axial image on Prostate MRI:

Figure 1. Prostate MRI Image Results Axial DWI Sequence with variations in b value (A) 1500 s/mm², (B) 2000 s/mm² and (C) 2500 s/mm² in the 2nd sample



Information :

- ▶ : Peripheral Zone
- ▶ : Transition Zone

Analysis of differences in image information, both overall anatomy and each anatomical criteria on Prostate MRI images, DWI axial section sequences with b values of 1500 s/mm², 2000 s/mm² and 2500 s/mm², then statistical analysis was carried out on 4 samples using the Friedman test. The following are the results of the Friedman test for the entire anatomy:

Table 2. Friedman test results for overall anatomy and mean rank on DWI Axial images on Prostate MRI with variations in b value 1500 s/mm², 2000 s/mm² and 2500 s/mm²

No	b value	Significance (p-value)	Information	Mean rank
1	1500 s/mm ²			1,93
2	2000 s/mm ²	0,020	Difference	2,38
3	2500 s/mm ²			1,70

From the Friedman test results in Table 2. above for the overall anatomy on the DWI Axial image on Prostate MRI with the b value variation having a p-value below 0.05. This means that there are differences in image information between the b values of 1500 s/mm², 2000 s/mm² and 2500 s/mm². Then after that continued the Friedman statistical test for each prostate anatomy criteria. The following are the results of the Friedman test for each anatomical criterion.

Table 3. Friedman test results for anatomical criteria and mean rank on DWI Axial images on Prostate MRI with variations in b value 1500 s/mm², 2000 s/mm² and 2500 s/mm²

No	Anatomical Criteria	b value (s/mm ²)	Significance (p-value)	Information	Mean rank
1	Peripheral Zone	1500	0,023	Difference	2.38
		2000			2.62
		2500			1.00
2	Central Zone	1500	0,368	No difference	2.12
		2000			2.12
		2500			1.75
3	Transition Zone	1500	0,037	Difference	2.12
		2000			2.75
		2500			1.12
4	Prostatic Capsule	1500	0,717	No difference	1,75
		2000			2.12
		2500			2.12
5	Seminal Vesicles	1500	0,093	No difference	1.50
		2000			2.62
		2500			1.88
6	Lymph Node	1500	0,135	No difference	2.12
		2000			2.12
		2500			1.75
7	Prostate Weight	1500	0,223	No difference	1.62
		2000			2.38
		2500			2.00

From the results of the Friedman test in Table 3. above it can be seen that the p-value for the anatomy of the central zone, prostatic capsule, seminal vesicle, lymph node, and prostate weight is above 0.05 or in other words there is no difference in image anatomical information from the three variations of b value. However, it is different from the anatomy of the peripheral zone and transition zone where the p-value is below 0.05, meaning there is a difference in image anatomical information between the b value of 1500 s/mm², 2000 s/mm² and 2500 s/mm² on the DWI Axial image on MRI of the Prostate.

Image Analysis Results with the Most Optimal B Value Variations in DWI Axial Images in MRI Prostate Cancer Cases

The analysis results of each assessment of anatomical image information are obtained by looking at the mean rank of the Friedman test both overall and each anatomical criteria to determine the image information with the most optimal b value on DWI Axial images on Prostate MRI. The following are the overall mean rank results of the Friedman test.

Based on the results of the mean rank value in Table 2. above, it can be seen that the mean rank value of the Friedman test as a whole on DWI Axial images on Prostate MRI, where the b value variation of 2000 s/mm² has the highest mean rank value compared to the b value variations of 1500 s/mm² and 2500 s/mm².

Based on Table 3. above, it can be seen that the mean rank value of the Friedman test each anatomical criteria on axial DWI images on Prostate MRI, where a b value of 2000 s/mm² generally has the highest mean rank value compared to variations of 1500 s/mm² and 2500 s/mm² both anatomy peripheral zone, central zone, transition zone, prostatic capsule, seminal vesicles, lymph nodes, and prostate weight.

3.1. Differences in DWI Axial anatomical image information on prostate MRI in cancer cases between b values of 1500 s/mm², 2000 s/mm² and 2500 s/mm²

From the results of the Cohen's Kappa test, it shows that the level of agreement on images with varying b values of 1500 s/mm², 2000 s/mm² and 2500 s/mm² is quite good (fair). Based on the results of Friedman's non-parametric statistical test, overall there is a significant difference in DWI Axial images on Prostate MRI with variations in b values with p-values <0.05. The overall difference in the image can occur because the higher the b value, the intensity of the diffusion signal and the sensitivity of the diffusion will increase, the increased intensity of the diffusion signal in normal tissue will appear darker and in abnormal organs will appear

brighter in the displayed image [2]. This means that if the b value is higher, the MRI signal will also increase. The signal is related to the eachational field strength of the system and increases as activity changes energy [9]. Based on the above, if the b value increases or decreases, it will affect the signal intensity so that changes can occur in the anatomical image information.

Based on the results of Friedman's non-parametric statistical test specifically each anatomic criteria, it shows that there are significant differences for the anatomy of the peripheral zone and transition zone because the higher the b value, the noise generated will increase compared to the low b value and vice versa [10]. This increase in noise will make it difficult for doctors to see the sharpness of tissue [11].

In the anatomy of the peripheral zone and transition zone, there are significant differences in each variation used. Figure 1 shows that the anatomical features of the peripheral zone and transition zone are increasingly hyperintense as the b value increases because there are differences in signal intensity for each variation of the b value. Then in the anatomy of the central zone, prostatic capsule, seminal vesicle, lymph node, and prostate weight, there are no significant differences in anatomical information for all variations of the b value because the anatomical size is so small that it cannot be seen clearly and based on the results of the mean rank b value of 2000 s/mm² is the highest value, because the higher the b value, the more noise the anatomy has.

3.2. Anatomical image information with the most optimal b value variations in DWI Axial anatomical images in MRI prostate cancer cases

DWI sequences can be used to detect cancer and estimate the severity of cancer. The degree of cancer can also affect the clarity and brightness of the MRI image. The higher the level of cancer, the brighter the MRI image [12]. Based on the results of Friedman's non-parametric test, the mean rank was obtained for axial DWI images on Prostate MRI to find out the most optimal image information by varying the b value parameter both as a whole and each anatomic criteria. The mean rank results showed that the b value was 2000 s/mm² has the highest mean rank compared to the b values of 1500 s/mm² and 2500 s/mm² because the use of DWI sequences must be optimized by using the right b value parameter so that it can be set and noise can be minimized [10]

Based on the results of the research that has been done, the b value of 2000 s/mm² is the most optimal value in producing MRI images of the prostate in cancer cases because the signal intensity generated is neither too high nor too low so that the prostate cancer tissue looks more hyperintense than the image results. b value is 1500 s/mm² and there is also not much noise compared to b value 2500 s/mm². This is because the smaller the signal intensity produced by the b value, the less noise produced and the image of the cancer is not too hyperintense so that it interferes with the image results. Likewise, if the signal intensity is too high it will cause a lot of noise that disturbs the image.

4. CONCLUSION AND RECOMMENDATION

The conclusion is Axial DWI anatomical images on prostate MRI for cancer cases between b values 1500 s/mm², 2000 s/mm² and 2500 s/mm² there is a significant difference in anatomical image information because the signal intensity generated is neither too high nor too low so that the tissue from prostate cancer it looks more hyperintense and there is also not much noise. Axial DWI anatomical image on Prostate MRI in cancer cases with a b value variation of 2000 s/mm² produces the most optimal image information.

The recommendation is In prostate MRI examination, cancer cases with DWI sequences at South Jakarta Private Hospital should use parameter b value 2000 s/mm². For future research, it is better if the number of patient samples needs to be increased and for the grading of prostate cancer cases it needs to be made more detailed.

Acknowledgements

I would like to thank Allah SWT, Universitas Muhammadiyah Purwokerto, my sueachvisor, Mr. Fani Susanto, M.Tr.Kes, who has helped and supported the process of research and writing of this journal. I also want to thank my parents who have provided prayers as well as help and support, both material and moral.

REFERENCES

- E. Goljan, *Rapid Review Pathology*, 5th ed. Elsevier Health Sciences, 2018.
- C. Westbrook, *Handbook of MRI Technique*, 4th ed. SPi Publisher Services, Pondicherry, India, 2014.
- A. Panda, V. Gulani, and L. Ponsky, *A Practical Guide Reading MRI of the Prostate*. Springer, 2020.
- Q. Zeng, B. Jiang, F. Shi, C. Ling, F. Dong, and J. Zhang, "Bright edge sign on high b-value diffusion-weighted imaging as a new imaging biomarker to predict poor prognosis in glioma patients: A retrospective pilot study," *Front Oncol*, vol. 9, 2019.

- T. Metens, D. Miranda, J. Absil, and C. Matos, "What is the optimal b value in diffusion-weighted MR imaging to depict prostate cancer at 3T?," *European Radiology*, vol. 22, no. 3, pp. 703–709, 2012. doi: 10.1007/s00330-011-2298-9.
- Y. Ueno *et al.*, "Ultra-high b-value diffusion-weighted MRI for the detection of prostate cancer with 3-T MRI," *Journal of Magnetic Resonance Imaging*, vol. 38, no. 1, pp. 154–160, 2013, doi: 10.1002/jmri.23953.
- S. Feuerlein, M. S. Davenport, A. Krishnaraj, E. M. Merkle, and R. T. Gupta, "Computed high b-value diffusion-weighted imaging improves lesion contrast and conspicuity in prostate cancer," *Prostate Cancer Prostatic Dis*, vol. 18, no. 2, pp. 155–160, 2015, doi: 10.1038/pcan.2015.5.
- Faqirilmu.com, "Sampel Adalah : Syarat, Contoh dan Cara Menentukan Besar Sampel," 2022. [Online]. Available: <https://www.faqirilmu.com/2022/10/pengertian-syarat-contoh-dan-cara-menentukan-besar-sampel.html>
- R. George, J. Dela Cruz, R. Singh, and D. R. Ilangovan, "MRIMASTER," *London, United Kingdom*. 2022. [Online]. Available: <https://mrimaster.com/>
- Z. Koc, G. Erbay, S. Ulasan, G. Seydaoglu, and F. Aka-Bolat, "Optimization of b value in diffusion-weighted MRI for characterization of benign and malignant gynecological lesions," *Journal of Magnetic Resonance Imaging*, vol. 35, no. 3, pp. 650–659, 2012.
- T. Geith *et al.*, "Comparison of qualitative and quantitative evaluation of diffusion-weighted MRI and chemical-shift imaging in the differentiation of benign and malignant vertebral body fractures," *American journal of roentgenology*, vol. 199, no. 5, pp. 1083–1092, 2012.
- M. I. Pratama, "Klasifikasi Citra MRI sebagai alat bantu diagnosis Jenis Penyakit Tumor Otak Menggunakan Transfer Learning VGG-16," *Doctoral dissertation, UGM*. 2022. [Online]. Available: <http://etd.repository.ugm.ac.id/penelitian/detail/214628>